

Maxillary Prosthodontic Rehabilitation with Fixed-removable Partial Denture Using Extra Coronal Attachment: A Clinical Case Report

Sameh Rzigui^{1*}, Amel Labidi¹, Lamia Mansour¹ and Mounir Trabelsi¹

¹*Department of Removable Prosthetics, ABCDF Laboratory, Faculty of Dental Medicine, University of Monastir, Tunisia.*

Authors' contributions

This work was carried out in collaboration among all authors. Author SR designed the study, performed the statistical analysis, wrote the protocol and wrote the first draft of the manuscript. Authors AL and LM managed the analyses of the study. Author MT managed the literature searches. All authors read and approved the final manuscript.

Article Information

Editor(s):

(1) Dr. Armando Montesinos Flores, Department of Orthodontics, Faculty of Odontology, Postgraduate Studies and Research Division, National Autonomous University of Mexico, Mexico.

Reviewers:

(1) Julie O. Omo, University of Benin, Nigeria.

(2) Adam Husein, Universiti Sains Malaysia, Malaysia.

(3) Wagih Mommtaz Ghannam, Mansoura University, Egypt.

Complete Peer review History: <http://www.sdiarticle4.com/review-history/53784>

Case Study

Received 01 November 2019

Accepted 07 January 2020

Published 14 January 2020

ABSTRACT

The rehabilitation of partially edentulous patients is a real challenge for prosthodontists. Attachment retained cast partial dentures can be an excellent option when economic or anatomic conditions do not permit the use of dental implants. They give functionally and esthetically good results. This article describes rehabilitation of a partially edentulous patient with attachment retained hybrid prosthesis.

Keywords: Fixed denture; removable partial denture; extra coronal attachment.

1. INTRODUCTION

Rehabilitation of partial edentulism can be done by several methods out of which one treatment

modality is implant retained prosthesis: This option needs a sufficient residual bone, a good general health status and a good economic situation of patients. Fixed dentures may not be

*Corresponding author: Email: samehrzigui@gmail.com;

recommended when remaining teeth are unable to withstand oral changes or when the edentulism is terminal or extended [1].

Combined prosthesis constitutes a feasible option if implant retained or fixed prosthesis are not possible and a good alternative to a conventional clasp retained removable partial denture. This type of prosthesis not only provide an esthetic result, also it gives functional advantage of fixed denture that leads to decreased compression of edentulous ridge and enhanced phonetics and mastication [2].

This clinical case report describes a maxillary prosthodontic rehabilitation with a combined prosthesis: a fixed dental prosthesis designed to interfere with a removable cast framework partial denture (RPD) retained by an extra coronal attachment type Rhein⁸³. (Rhein 83 Attachment USA).

2. CLINICAL CASE PRESENTATION

A 52 years old female, with good general health status, was addressed to the Prosthodontics Department at the Faculty of Dental Medicine, University of Monastir, Tunisia.

She was unsatisfied with her smile and suffered from compromised masticatory function.

Clinical and radiographic examinations (Fig.1) revealed lack of posterior support, a little loss of occlusal vertical dimension, an alteration in the occlusal plane and a reduced vertical space.

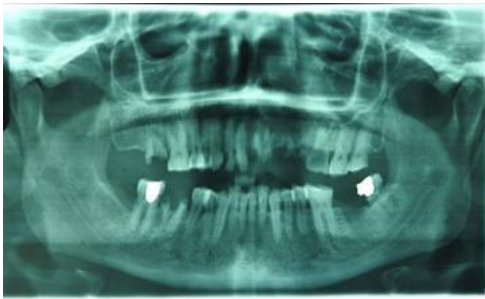


Fig. 1. Orthopantomogram before extraction of compromised teeth

The diagnosis of Kennedy-Applegate class I modified 1 edentulism in the maxillary arch was made.

Dental caries were found in the 11, 12 and 44 (Fig. 2)

After compromised teeth were extracted and periodontal clinical status established, remaining teeth were: 16, 15, 14, 13, 12, 11, and 27 presented good periodontal support.

Considering the extensive carious lesions, the maxillary right central and lateral incisor, were endodontically treated. Lateral incisor was reconstituted by an inlay core to get best retention value.

Diagnostic casts were articulated at the correct occlusal vertical dimension, and the treatment was carefully planned taking into account patient's esthetic demand and economical condition.

Inter-arch space was adequate for the use of precision attachments.

Treatment plan included rehabilitation of maxillary arch with combined fixed/removable prosthesis (using RHEIN⁸³ precision attachment) (Fig. 3) and fixed prosthesis in the mandibular arch. It was established and presented to the patient to obtain her consent.

Preparation of all maxillary remaining teeth was done (Figs. 4, 5) in order to be restored with fixed metal-ceramic bridge as well as 45 and 47.

Provisional acrylic resin crowns were fabricated and a provisional removable partial denture was created to replace missing teeth. Provisional restorations are an integral part of prosthodontic treatment pertaining to their importance as regard margin fidelity, function, occlusion, and esthetics [3].

Once the prosthodontic project had been restored by provisional restorations, we started the clinical steps. Gingival retraction was achieved by double wire methods and maxillary Impression was made with wash technique using silicone of low and heavy viscosity. (Vannini, France) (Fig. 6).

The final model was made in gypsum type IV mounted on semi adjustable articulator using a face bow. References are the centric relation and a correct occlusal vertical dimension.

In laboratory, the crowns have been waxed (Fig. 8) and the Patrice of the attachment was added to the distal surfaces of the abutment using a dental surveyor, lingual to the centre of proximal contour (Fig. 9). This ensures that the matrice parts do not interfere with esthetic and that fixed

elements were made according to an insertion path; in this case it's the vertical path.

In the laboratory the metal framework was made (Fig. 10) and the extra-coronal attachment attached. The lingual surfaces of the maxillary teeth were flattened to guide the insertion /removal path of the removable partial denture. The metal copings were examined and the marginal limits were verified. An adequate interocclusal distance allowed ceramic application. The unglazed ceramic was clinically tried and returned to the definitive cast. The

dental surveyor was again used to check the previously established insertion/removal path of the RPD. Porcelain buildup of fixed denture was completed (Fig. 11).

The fixed component including veneered metal-ceramic crowns and the patrices were tried in the patient mouth (Fig. 12) and a pick-up impression with acrylic custom tray and polyether was made. (Fig. 13) Polyether (3M ESPE Impregum™ Soft FRANCE) seems to be ideal for a pick up impression it s known for its precision and rigidity.

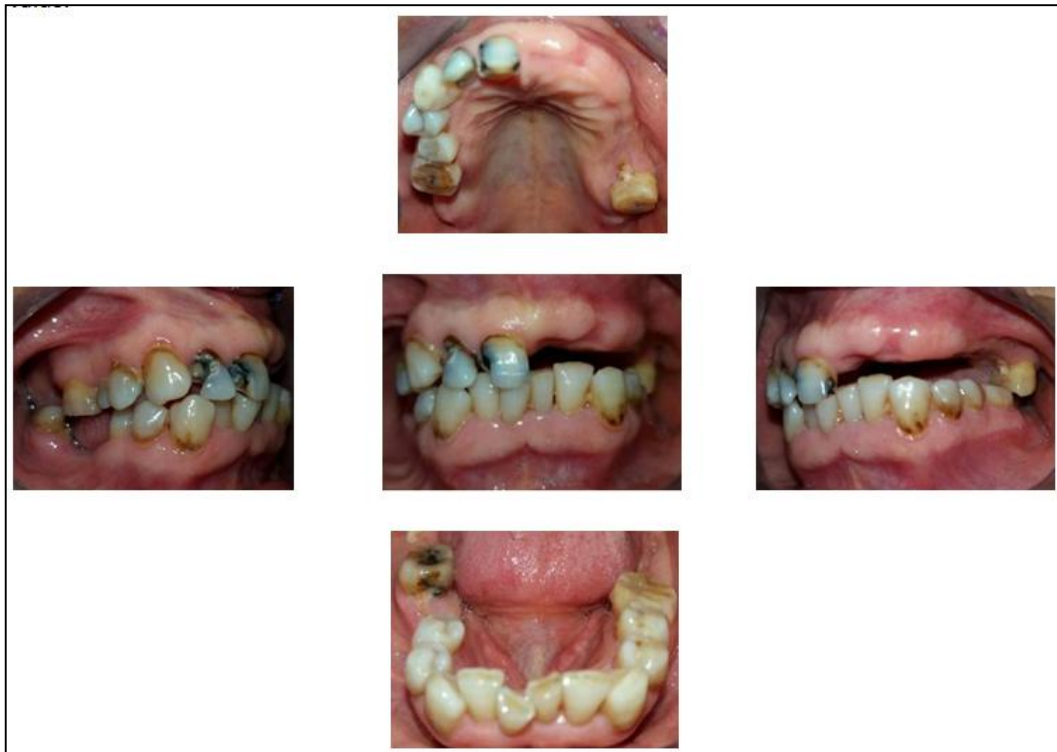

Fig. 2. Pretreatment intraoral view

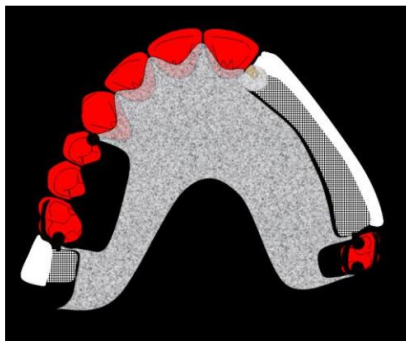


Fig. 3. Design of the prosthesis frame

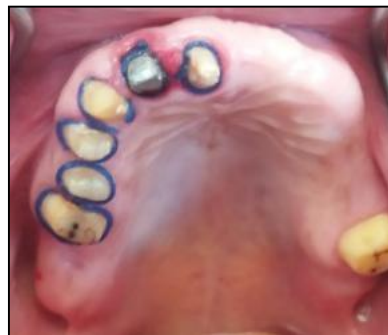

Fig. 4. Preparation of all remaining maxillary teeth

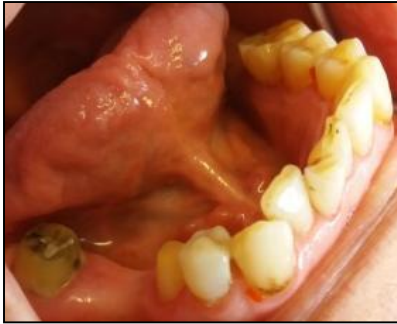

Fig. 5. Preparation of 45 and 47

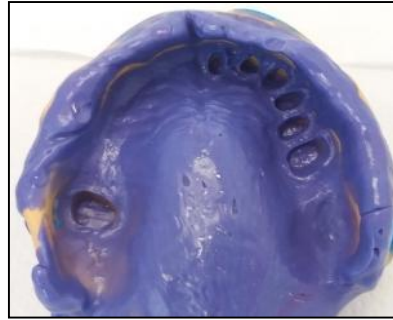


Fig. 6. Maxillary impression

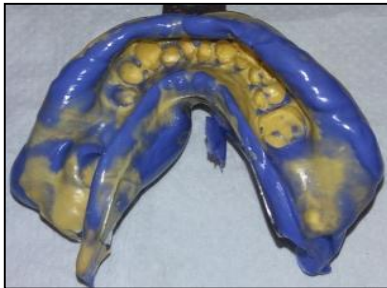

Fig. 7. Mandibular impression

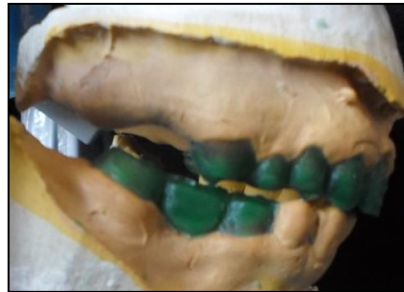

Fig. 8. Waxed crowns

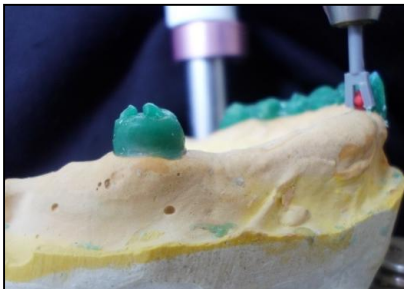


Fig. 9. Fixing the patrice of the attachment

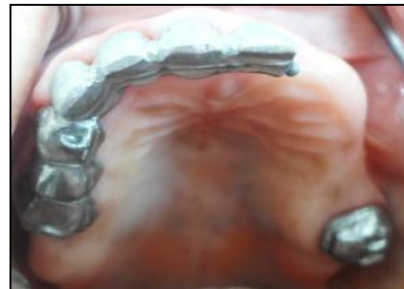

Fig. 10. Metal framework try-in

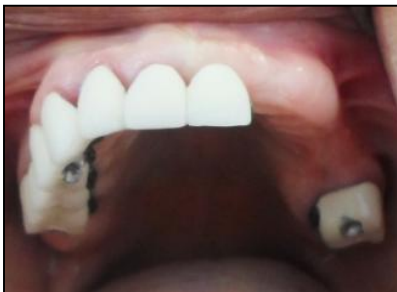

Fig. 11. Clinical try-in of fixed denture

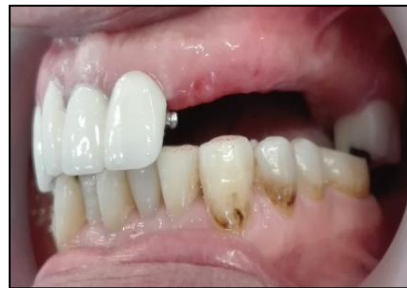

Fig. 12. Trying the finished bridge

Female replica of the attachment was attached to the cast male component (Fig. 14). The Fixed partial denture /cast assembly was duplicated with reversible hydrocolloid, and a refractory cast was produced. The RPD

framework was cast in a cobalt-chromium alloy and clinically tried to check the fitting. The artificial teeth were selected and positioned using the interim prostheses as form and color reference.

Wax-up of the cast framework was completed on the master cast, (Fig. 15) and care was taken during the finishing and sandblasting procedures of the casted fixed denture to avoid abrasive wear of the attachment (Fig. 16)

Maxillomandibular relation was recorded and mounted on semi-adjustable articulator immediately after framework try in. Teeth arrangement was done and wax try in done.

Occlusion and esthetics was verified in patient's mouth. Cast partial denture for maxillary arch was fabricated in heat cure denture base resin.

Female components of attachments were attached to cast partial denture by relining method after verifying occlusal contacts. It's a critical step because an incorrect positioning can result in a wrong fitting of the removable partial denture.

So, crowns had to be cemented and the framework had to be inserted simultaneously.

Retention was found to be satisfactory after insertion of cast partial in patient's mouth. The patient was instructed regarding oral hygiene, how to remove and insert the denture and the time to recall for matrices check, in order to have a good functionality.

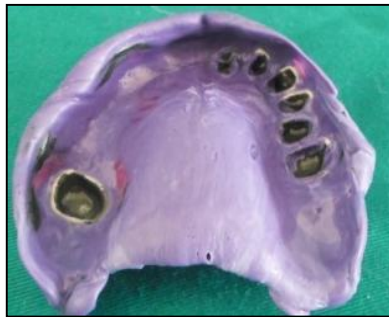

Fig. 13. Pick-up impression

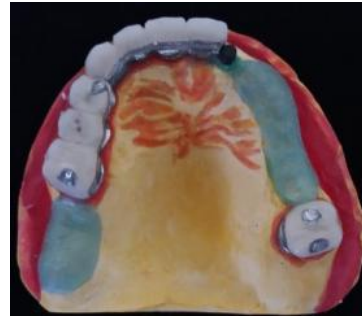

Fig. 14. Female replica fixed

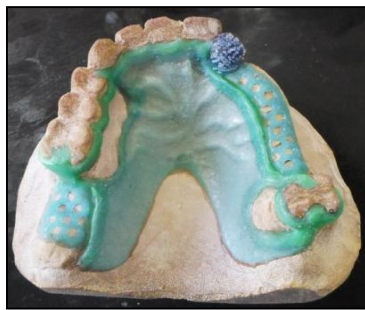

Fig. 15. Wax pattern fabrication of cast partial denture

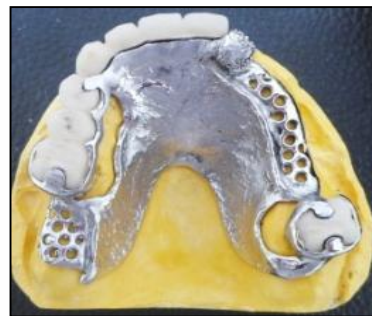

Fig. 16. Framework of maxillary cast partial

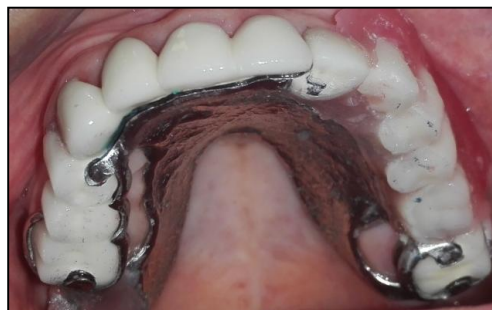

Fig. 17. Clinical try-in of RPD framework

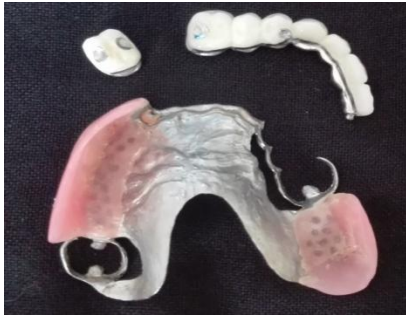

Fig. 18. Different parts of the combined prosthesis

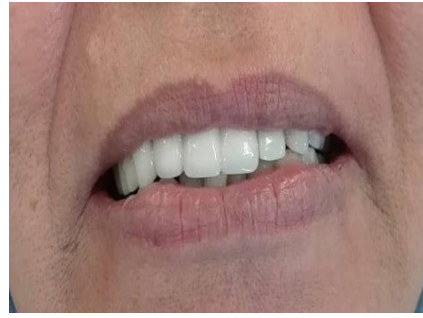

Fig. 19. Post-treatment frontal smile

The end result has provided patient satisfaction regarding the combination of fixed dentures and removable skeletal dentures using an extra coronal attachment.

Occlusion stabilization was achieved, improved chewing and good aesthetics.

3. DISCUSSION

The association between fixed and removable partial dentures by means of attachments is an important alternative for oral rehabilitation, particularly when the use of dental implants and fixed denture is limited or not indicated [1].

Attachment is a connector consisting of two or more parts. They are classified as semi precision and precision devices. In our case, we used a semi precision attachment type Rhein 83 which is cast from calculable patterns, while in precision attachments, the matrix-matrix portions are prefabricated on a metal alloy [4].

Among the advantages of an attachment-retained removable partial denture are the improvement in esthetics, as clasps are not used in the anterior region, and biomechanics, considering that lower torque is applied to the abutment teeth in a cervical direction during functional movements. Moreover, attachment helps to distribute forces equally between soft and hard tissues [5,6].

Attachments may also allow better cross arch force transmission and stabilization than clasps but this is determined by the type of attachment used, the number of guiding surfaces and the design of the framework [7,8].

The extra coronal attachment used in our case has a vertical freedom of movement with elastic retention; this elasticity controls the flexure and

constructs a resilient and shock absorbing prostheses [9,10].

Most of the studies have shown that attachment retained cast partial dentures gives better comfort, function, esthetics, less adjustments, protect abutment teeth and easy to clean [8].

The stress control on abutment is essential for the success of the prosthodontic rehabilitation which is achieved through accurate impression technique, broad coverage, stable denture base, a good shimming and proper selection of attachment [8,11].

Finally, long term success requires knowledge of important laboratory techniques, clinical skills; it depends also on biological factors, especially the periodontal ones [9,12].

4. CONCLUSION

Hybrid prosthesis is still a topical treatment despite advances in implantology. To succeed it, particularly in case of global rehabilitation, prosthodontists have to know how to state their indication and respect the chain of implementation. In fact, coordination between the prosthesis laboratory and the clinician is decisive.

In our case, through a composite prosthesis with attachment, we were able to restore masticatory and occlusal functions, namely the anterior guide, phonation and above all to ensure satisfactory esthetics. Maintenance is the key of a good long-term prognosis.

CONSENT AND ETHICAL APPROVAL

As per international standard guideline participant consent and ethical approval has been collected and preserved by the authors.

COMPETING INTERESTS

Authors have declared that no competing interests exist.

REFERENCES

1. Chronopoulos V, Sarafianou A, Kourtis S. The use of dental implants in combination with removable partial dentures: A case report. *J Esthet Restor Dent*. 2008; 20:355–364.
2. José Mauricio dos Santos Nunes Reis, Luciano Elias da Cruz Perez, Bruna Fernandes Moreira Alfenas. Maxillary rehabilitation using fixed and removable partial dentures with attachments: A clinical report. *Journal of Prosthodontics*. _ C-2013 by the American College of Prosthodontists. 2013;1–6.
3. Regish KM, Sharma D, Prithviraj DR: Techniques of fabrication of provisional restoration: An overview *International Journal of Dentistry*. 2011;6:134659.
4. Cristian Schuh, Jovito Adiel Skupien, Mauro Elias Mesko. Resilient attachments as an alternative to conventional cast clasp removable partial denture: 3-year follow-up. *J Indian Prosthodont Soc*. 2014;14 (Suppl. 1):S273–S278
5. Sakshi Gupta, Sapna Rani, Arpit Sikri, Aditya Kapoor. Attachment retained cast partial denture: Conventional and contemporary treatment perspectives. *International Journal of Oral Care and Research*. 2016;4(4):312-316.
6. Gopinadh Anne, Krishna Kishore Kadiyala H, Ravi Rakesh Dev J, Mohan Krishna Badisa. Full mouth rehabilitation using fixed partial denture & cast partial denture with attachments and conventional lower denture - A case report. *International Dental Journal of Students Research*. 2017;5(1):25-28.
7. Sharad Vaidya, Charu Kapoor, Yujika Bakshi, Sonam Bhalla. Achieving an esthetic smile with fixed and removal prosthesis using extracoronal castable precision attachments. *The Journal of Indian Prosthodontic Society*. 2015;15(3).
8. Gulshan Kumar Tomar, Mirna Garhnyak, Sitansu Sekhar Das, Shelly Roy. Cast partial denture retained using precision attachment – A case report. *IOSR Journal of Dental and Medical Sciences*. 2016; 15(7):V:94-99.
9. Agripina Zaharia, Aureliana Caraiane, Corina Ștefănescu, Rodica Murineanu. Fixed dentures combined with removable dentures retained with extracoronal attachments. *Ovidius Dentistry Journal*. 2014;1(1).
10. Makkar S, Chhabra A, Khare A. Attachment retained removable partial denture: A case report. *International Journal of Computing and Digital Systems*. 2011;2(2):39–43.
11. Naveen Gupta, Abhilasha Bhasin, Parul Gupta, Pankaj Malhotra. Combined Prosthesis with Extracoronal Castable precision Attachments: Case Reports in Dentistry; 2013. [Article ID: 282617:4]
12. D’Incau E, Séguéla V. Prothèse composite maxillaire et prothèse fixée mandibulaire. Démarche thérapeutique pour un traitement global. *Cah Prothèse*. 2008;143:13-24.

© 2019 Rzigui et al.; This is an Open Access article distributed under the terms of the Creative Commons Attribution License (<http://creativecommons.org/licenses/by/4.0>), which permits unrestricted use, distribution, and reproduction in any medium, provided the original work is properly cited.

Peer-review history:
The peer review history for this paper can be accessed here:
<http://www.sdiarticle4.com/review-history/53784>